



Alma Mater Europaea University – ECM
Journal of Health and Rehabilitation Sciences, 2025 Dec 20; 4(2), 1-10
Health Research

Functional and Anatomical Outcomes Assessed by Microperimetry Following Intravitreal Bevacizumab in Treatment-Naïve Centre-Involving Diabetic Macular Edema: A 3-Month Prospective Evaluation

Sanjay KUMAR MISHRA¹,
Tejinder SINGH AHLUWALIA²,
Rajpal VOHRA³,
Rohan CHAWLA³

¹Nims College of Allied and Health Care Sciences,
Nims University Rajasthan, Jaipur Rajasthan, India

²Department of Ophthalmology, Nims University,
Rajasthan, Jaipur, India

³Vitreo-Retina Services at Dr. Rajendra Prasad Centre
for Ophthalmic Sciences, All India Institute of Medical
Sciences (AIIMS), New Delhi 110029, India

Email: sanjaymishraknp@yahoo.com

Original Article

Received: 29-Aug-2025

Revised: 09-Oct-2025

Accepted: 18-Oct-2025

Online first: 19-Oct-2025

Abstract

Introduction: Diabetic macular edema (DME) remains a major cause of vision impairment worldwide. Intravitreal bevacizumab, though used off-label, is an established therapy for centre-involved DME (CI-DME). This study evaluated how effectively microperimetry complements standard measures—best-corrected visual acuity (BCVA) and central macular thickness (CMT)—in assessing treatment outcomes.

Methods: In this prospective observational study, 52 eyes with treatment-naïve CI-DME received three monthly bevacizumab injections. BCVA, CMT (via OCT), and mean retinal sensitivity (by microperimetry) were recorded at baseline, one month, and three months. Statistical analyses included the Wilcoxon signed-rank test for repeated measures and Spearman's rank correlation for structure–function relationships.

Results: After three months, mean BCVA improved from 0.50 ± 0.095 to 0.67 ± 0.088 ($p < 0.001$), while CMT decreased from $401.9 \pm 87.6 \mu\text{m}$ to $329.5 \pm 23.2 \mu\text{m}$ ($p < 0.001$). Mean retinal sensitivity rose from 14.96 ± 1.01 dB to 16.50 ± 1.39 dB ($p < 0.001$). Improvement in BCVA correlated positively with both CMT reduction ($\rho = 0.340$, $p = 0.014$) and sensitivity gain ($\rho = 0.412$, $p = 0.004$), while CMT reduction correlated inversely with sensitivity improvement ($\rho = -0.367$, $p = 0.009$).

Conclusion: Three consecutive bevacizumab injections resulted in significant anatomical and functional recovery in eyes with CI-DME. The consistent correlations between macular structure and function underscore the value of microperimetry as a sensitive, complementary tool for evaluating therapeutic response beyond standard acuity and OCT metrics.

Keywords: Diabetic Macular Edema, Bevacizumab, Central Macular Thickness, Anti-VEGF, Retinal Sensitivity, Microperimetry, OCT, Intravitreal Injection

Citation: Mishra, S.K., Ahluwalia, T.S., Vohra, R., Chawla, R. (2025) Functional and Anatomical Outcomes Assessed by Microperimetry Following Intravitreal Bevacizumab in Treatment-Naïve Centre-Involving Diabetic Macular Edema: A 3-Month Prospective Evaluation. *Journal of Health and Rehabilitation Sciences*, 2025 Dec 20; 4(2), 1–10. <https://doi.org/10.33700/jhrs.4.2.172>

Copyright ©2025 Mishra, S.K., Ahluwalia, T.S., Vohra, R., Chawla, R. This is an open-access article distributed under the terms of the Creative Commons 4.0 International License (CC BY 4.0)

Corresponding address:

Sanjay KUMAR MISHRA

Nims College of Allied and Health Care Sciences, Nims University
Rajasthan, Jaipur Rajasthan, India

Email: sanjaymishraknp@yahoo.com

1. Introduction

As per the recent World Health Organisation estimates, the global diabetic population is projected to increase by 47% by 2045 (Sun et al., 2022; Udaondo et al., 2022). The situation in India is even worse, as the diabetic population is going to increase by 86% by the same period. And that is why India is also referred to as the diabetic capital of the world (Magliano et al., 2021).

Due to the increasing diabetic population, diabetic macular edema (DME) is one of the leading causes of vision loss in the general population, characterised by increased macular thickness resulting from increased vascular permeability and ischemia, leading to fluid accumulation.

Centre-involving diabetic macular edema causes significant deterioration of vision, thereby deteriorating the quality of life of affected individuals (Wong et al., 2016). The prevalence of DME reported by various authors ranges from 20% to 30%, indicating an urgent need for effective treatment modalities (Yau et al., 2012).

Bevacizumab, an anti-vascular endothelial growth factor (anti-VEGF) agent, has emerged as the most cost-effective option among the various intravitreal injections utilised in the management of diabetic macular edema (DME).

This mechanism operates by inhibiting VEGFs, which are critical mediators of neovascularisation and heightened vascular leakage in the retina (Ferrara & Adamis, 2016).

Numerous studies indicate that this drug positively affects visual acuity and decreases central macular thickness (CMT) (Brown et al., 2006; Nguyen et al., 2012).

The impact of bevacizumab on retinal sensitivity, assessed through microperimetry, remains under-researched.

Microperimetry is a tool used to evaluate retinal sensitivity in patients with impaired central visual function, providing insights into localised retinal responses across the posterior pole that may not be comprehensively assessed by visual acuity alone (Laishram et al., 2017).

Microperimetry enables the assessment of functional changes in the retina, which can be particularly important in understanding the effects of treatment in patients with centre involving diabetic macular edema CI-DME) (Vujosevic et al., 2010).

The primary purpose of conducting this study was to evaluate the impact of intravitreal bevacizumab injections on microperimetry sensitivities and visual acuity in treatment-naïve CI-DME patients over three months post-injection.

Additionally, by correlating changes in microperimetry sensitivities with visual acuity, this current study aims to provide insight into the relationship between retinal sensitivity in the broader area of the posterior pole and visual acuity outcomes.

2. Materials and methods

A prospective longitudinal observational analysis was designed and conducted at a tertiary teaching hospital and medical institute.

Ethical clearance was obtained from the institutional ethical committee before starting the study, and informed consent was obtained from all the patients.

2.1 Definition of Treatment-Naïve CI-DME

For this study, we defined treatment-naïve CI-DME as DME without any prior treatment, including intravitreal depot steroids, anti-VEGF agents, laser photocoagulation, or vitrectomy.

CI-DME is characterised by CMT involving the foveal and surrounding region, confirmed by the presence of intra- or sub-retinal fluid on fundus fluorescein angiography (FFA) and/or CMT of ≥ 305 μm as measured by spectral-domain optical coherence tomography (SD-OCT) using the Heidelberg Engineering SPECTRALIS HRA+OCT (Heidelberg Engineering, Inc., Franklin, MA, USA).

2.2 Participants

2.2.1 Sample Size and Power Calculation

The sample size for this study was determined using a power analysis to ensure adequate statistical validity.

The calculation was based on an expected correlation coefficient (ρ) between retinal sensitivity assessed by microperimetry and CMT. Assuming a 95% confidence level ($Z_{\alpha/2} = 1.96$) and 80% statistical power ($Z_{\beta} = 0.84$), the minimum required sample size was estimated to be 47 eyes.

To compensate for potential dropouts or incomplete data during follow-up, an additional 10% was included, resulting in a final target enrolment of 52 eyes.

This sample size was considered sufficient to detect meaningful correlations between functional and anatomical outcomes.

2.3 Inclusion and exclusion criteria

Consecutive patients suitable for treatment with intravitreal injections of bevacizumab fulfilling the inclusion criteria of age 18 years and above, regardless of gender, diagnosed with treatment-naïve CI-DME, with best corrected visual acuity (BCVA) criterion of 6/12 (20/60, 0.5) or less, and CMT criterion of ≥ 305 μm as measured by SD-OCT. Additionally, sufficient media clarity, pupillary dilation, and cooperation for all types of testing, as well as a willingness to participate in the study, were among the key criteria.

We excluded patients with a history of previous treatment for CI-DME, or those with retinal conditions such as age-related macular degeneration, pathological myopia, significant cataract, glaucoma, or who were unwilling to participate in the study.

2.4 Tools

The following tools and equipment were used in the study: for colour fundus photography, FFA, and SD-OCT, a Heidelberg Engineering SPECTRALIS HRA+OCT was employed. For performing microperimetry, a MAIA (Centervue, Padova, Italy) was used.

2.5 Procedure

At baseline visit, a detailed history of ophthalmic and systemic illnesses, family history, prior treatments,

and demographic details were taken. BCVA was assessed using a Snellen/Early Treatment Diabetic Retinopathy Study (ETDRS) visual acuity chart, and the values were converted to decimal notation. Slit lamp examination was performed to rule out significant anterior-segment disorders, and intraocular pressure was measured using non-contact tonometry.

A dilated retinal examination was conducted using 78D/90D lenses using the indirect ophthalmoscopic technique (figure 1).

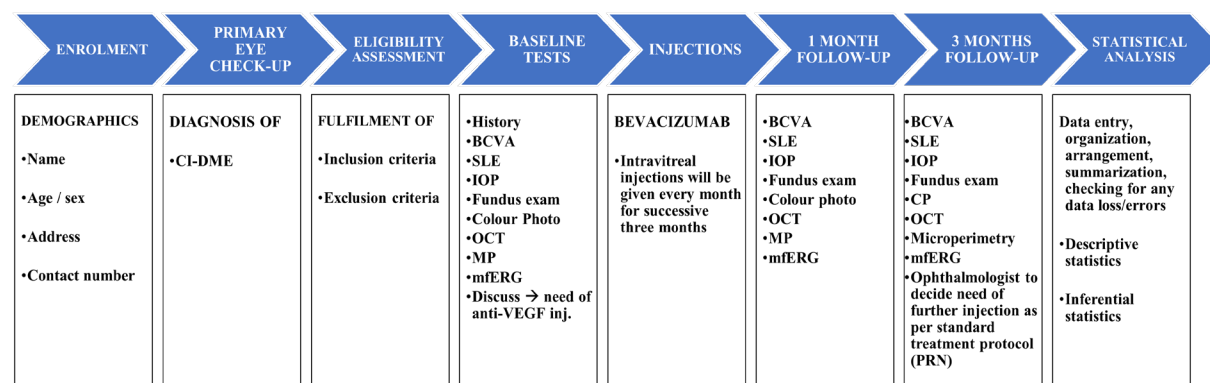


Fig. 1: Schematic diagram of the study protocol, detailing the sequence of clinical evaluations and measurements. (BCVA: best corrected visual acuity; CMT: central macular thickness; CI DME: center-involving diabetic macular edema; OCT: optical coherence tomography; VEGF: vascular endothelial growth factor; CP: color photo; IOP: intraocular pressure; SLE: slit lamp examination)

2.5.1 Patient Consent Procedures

Before commencing the study, ethical approval was obtained from the Institutional Ethics Committee of the All-India Institute of Medical Sciences, New Delhi, ensuring that every step of our study adhered to the Declaration of Helsinki guidelines.

We carefully explained the study's aims, the specific procedures involved—such as injections and all the tests (BCVA, OCT, microperimetry)—and any potential risks or benefits of participating. Participants were made fully aware that their involvement was entirely voluntary, and they could leave the study at any time without giving a reason, without it affecting their medical care. We also gave them ample time to ask questions, and we answered all their inquiries to their satisfaction. Only once they had clearly understood everything and confirmed their willingness to participate did each patient sign a written informed consent form. To protect their privacy, all participant data was handled with the utmost confidentiality throughout the study and in any reports.

2.5.2 Intravitreal Injection Protocol and Follow-Up

Intravitreal bevacizumab injections of Avastin® (Roche/Genentech, distributed in India by Cipla Ltd.) were given in a minor operating theatre under aseptic conditions to minimise the risk of endophthalmitis

later. The drug was used as 'off label' because it is not approved by the agencies such as United States Food and Drug Administration or European Medicines Agency for this indication. But it is routinely used in clinical settings owing to its demonstrated efficacy in prior studies and its cost effectiveness. The procedure was performed under the effect of topical anaesthesia, following the guidelines provided by the American Academy of Ophthalmology. The injection protocol included anaesthesia of the eye with a topical aesthetic agent, such as proparacaine. Then, a 5-10% povidone-iodine solution was applied over the eyelids and around the eye. Subsequently, a sterile speculum was inserted to keep the eye open during the injection. And finally, a dose of 1.25 mg of bevacizumab in a volume of 0.05 mL was injected intravitreally. Patients were monitored for a short time after the injection for any immediate adverse effects. Each patient received a loading dose of three, monthly injections (at baseline, 4 weeks, and 8 weeks). Follow-up visits were conducted at baseline, 1 month, and 3 months, during which BCVA, CMT (using SD-OCT), and retinal sensitivity (using microperimetry) were recorded.

2.5.3 Statistical Analysis

All collected data were carefully entered into Microsoft Excel for organisation and subsequently analysed using IBM SPSS Statistics for Windows, Version 27.0 (IBM Corp., Armonk, NY, USA).

Continuous variables, such as age, were summarised as mean \pm standard deviation (SD), while categorical variables, such as gender, were presented as frequency and percentage.

For inferential analysis, the paired t-test was used for comparing normally distributed continuous variables, and the McNemar test was applied to evaluate categorical data across time points. The Spearman's rank correlation coefficient (ρ) was used to assess the relationship between two continuous variables.

A p-value < 0.05 was considered statistically significant for all analyses.

3. Results

3.1 Participant Demographics

A total of 52 patients (26 males, 26 females) suffering from treatment-naïve CI-DME were included in the study ($n=52$). Mean age was 52.4 years ($SD = 7.1$). Mean best-corrected visual acuity (BCVA) was 0.50 ($SD = 0.095$) in decimal notation, mean central macular thickness (CMT) was 401.9 μm ($SD = 87.6$), and mean microperimetry – mean retinal sensitivity was 14.962 dB ($SD=1.009$) at baseline. The demographic and baseline values are summarised in Table 1.

Table 1: Baseline demographic and clinical characteristics of study participants ($N = 52$)

Characteristic	Value
Mean age (years)	52.4 ($SD = 7.1$)
Male/Female (n)	26/26 (50%/50%)
Mean BCVA (Decimal)	0.50 ($SD = 0.095$)
Mean CMT (μm)	401.885 ($SD = 87.566$)
Mean Microperimetry – Mean Retinal Sensitivity (dB)	14.962 ($SD=1.009$)

Note: $N = 52$ eyes from 52 patients. BCVA = Best-Corrected Visual Acuity. CMT = Central Macular Thickness. dB = decibel

3.2 Best Corrected Visual Acuity (BCVA), Central Macular Thickness (CMT), and Microperimetry – Mean Retinal Sensitivity (dB) Change

After three consecutive monthly intravitreal injections of bevacizumab, significant improvements

were observed in both functional and anatomical parameters.

Mean BCVA showed a progressive and statistically significant improvement from 0.50 ± 0.095 at baseline to 0.61 ± 0.092 at 1 month and 0.67 ± 0.088 at 3 months (paired t-test, $p < 0.001$ for both comparisons) (Table 2, Figure 2).

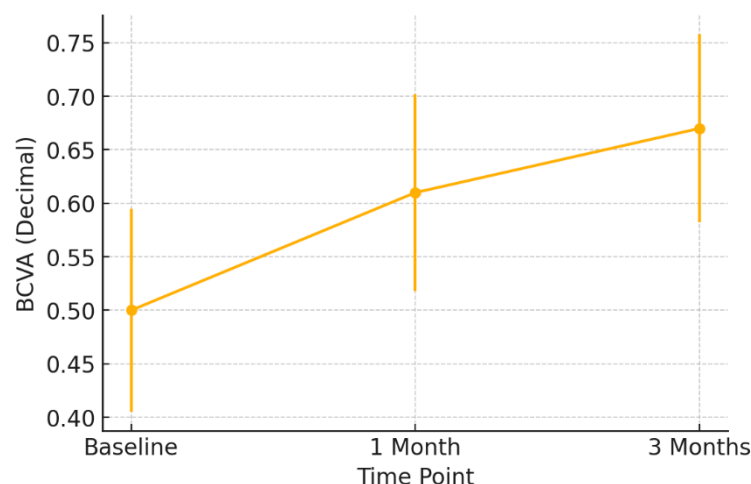


Fig. 2: Change in Best-Corrected Visual Acuity (BCVA) over time.

Similarly, mean CMT demonstrated a significant reduction from $401.9 \pm 87.6 \mu\text{m}$ at baseline to $337.9 \pm 23.7 \mu\text{m}$ at 1 month and $329.5 \pm 23.2 \mu\text{m}$ at 3

months ($p < 0.001$, repeated-measures ANOVA) (Table 2, Figure 3).

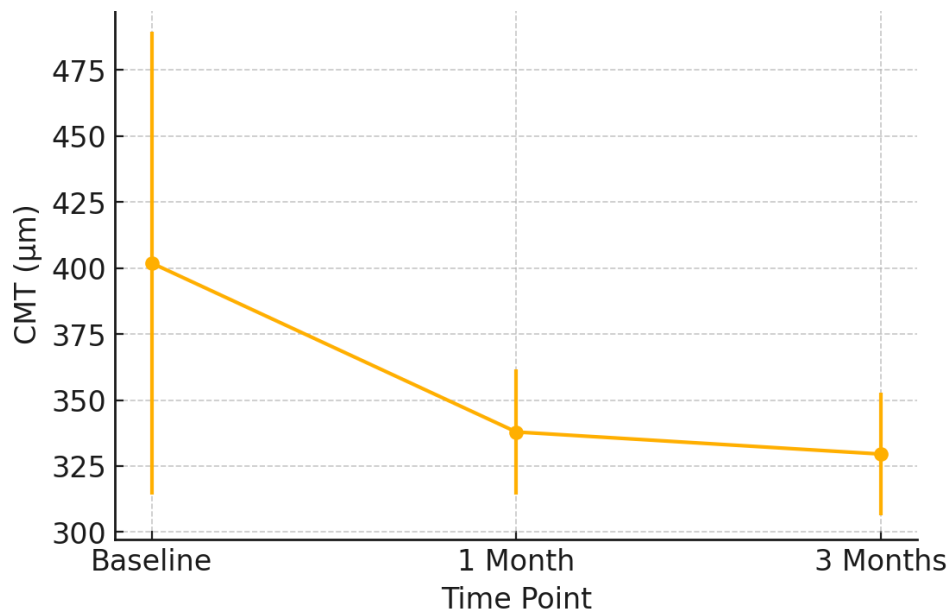


Fig. 3: Change in Central Macular Thickness (CMT) over time.

Correspondingly, mean Retinal Sensitivity assessed by Microperimetry increased significantly from $14.96 \pm 1.01 \text{ dB}$ at baseline to $16.08 \pm 1.20 \text{ dB}$ at 1 month and $16.50 \pm 1.39 \text{ dB}$ at 3 months ($p < 0.001$,

ANOVA), indicating a parallel functional improvement in retinal responsiveness (Table 2, Figure 4).

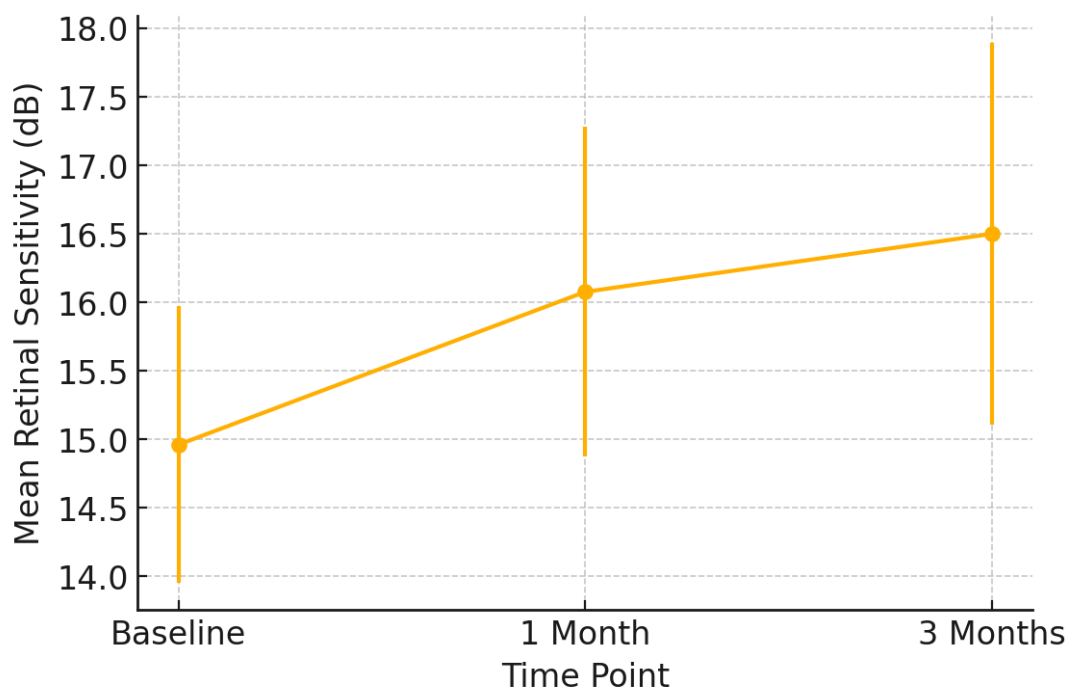


Fig. 4: Change in Mean Retinal Sensitivity (Microperimetry) over time.

Table 2 presents the changes observed over the study period in the BCVA, CMT, and mean retinal sensitivity at baseline, 1-month, and 3-month follow-

ups. There was a statistically significant improvement in BCVA as compared to baseline mean of 0.50 ± 0.095 to 0.61 ± 0.092 at 1 month ($p < 0.001$)

and further to 0.67 ± 0.088 at 3 months ($p < 0.001$). Likewise, CMT significantly decreased from a baseline mean value of $401.885 \pm 87.566 \mu\text{m}$ to $337.904 \pm 23.724 \mu\text{m}$ at 1 month and $329.538 \pm 23.249 \mu\text{m}$ at 3 months ($p < 0.001$ for both comparisons). The mean retinal sensitivity showed a progressive improvement from 14.962 ± 1.009 dB at

baseline to 16.077 ± 1.202 dB at 1 month and 16.500 ± 1.393 dB at 3 months ($p < 0.001$), indicating a gradual improvement in localised retinal function. All the above findings highlight those anatomical and functional parameters significantly improved following intravitreal injections of bevacizumab in patients suffering from CI-DME.

Table 2: Comparison of functional and anatomical parameters over time following treatment in eyes with diabetic macular edema

Parameter	Baseline	1 Month	3 Months	P-value (ANOVA)
Best-Corrected Visual Acuity (BCVA, Decimal)	0.50 ± 0.095	0.61 ± 0.092	0.67 ± 0.088	< 0.001
Central Macular Thickness (CMT, μm)	401.885 ± 87.566	337.904 ± 23.724	329.538 ± 23.249	< 0.001
Microperimetry – Mean Retinal Sensitivity (dB)	14.962 ± 1.009	16.077 ± 1.202	16.500 ± 1.393	< 0.001

Note: BCVA = Best-Corrected Visual Acuity. CMT = Central Macular Thickness

3.3 Correlation Analysis

Correlation analyses were performed to investigate the correlations between functional and anatomical markers during the research period. A considerable and statistically significant association was identified between the enhancement in BCVA and the decrease in CMT from baseline to 3 months (Spearman's $\rho = 0.340$, $p = 0.0137$). A favourable association was identified between enhancements in best-corrected visual acuity (BCVA) and increases in mean retinal sensitivity assessed by microperimetry ($\rho = 0.412$, $p = 0.004$).

In contrast, CMT reduction exhibited a negative connection with the increase in retinal sensitivity ($\rho = -0.367$, $p = 0.009$), indicating that narrower maculae post-treatment were linked to elevated sensitivity levels on microperimetry. Collectively, these findings underscore a consistent correlation between anatomical restoration and functional enhancement—specifically regarding visual acuity and retinal sensitivity—following intravitreal bevacizumab therapy, thereby emphasising the supplementary significance of microperimetry in evaluating macular function beyond traditional OCT metrics.

Table 3: Spearman's correlation between functional and anatomical parameters following intravitreal bevacizumab injections (N = 52)

Parameter Pair	Spearman's ρ	p-value	Interpretation
BCVA Improvement vs. CMT Reduction	0.340	0.014	Moderate positive correlation — better visual acuity associated with reduced macular thickness
BCVA Improvement vs. Retinal Sensitivity Gain	0.412	0.004	Moderate positive correlation — greater BCVA improvement linked with higher retinal sensitivity
CMT Reduction vs. Retinal Sensitivity Gain	-0.367	0.009	Moderate negative correlation — lower CMT values correspond with improved retinal sensitivity

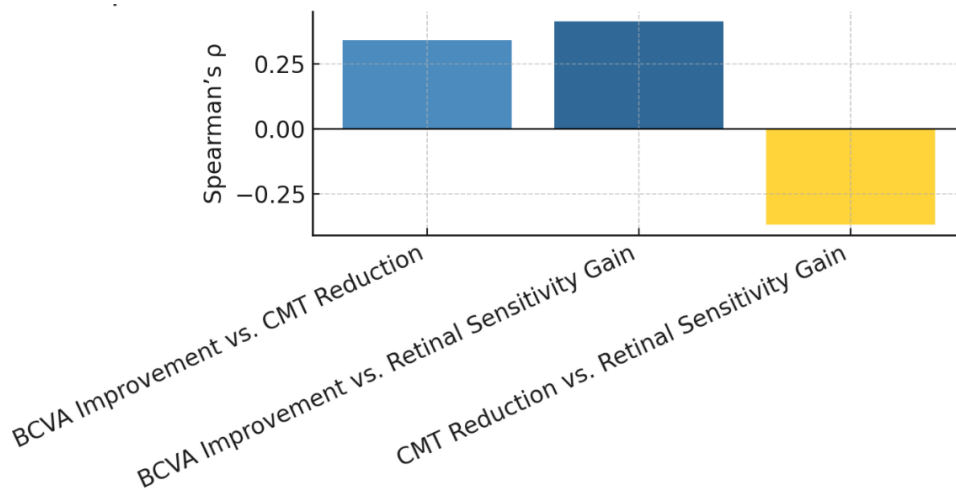


Fig. 5: Spearman's correlation between functional and anatomical parameters following intravitreal bevacizumab therapy

4. Discussion

This prospective observational study demonstrates that three consecutive monthly intravitreal injections of bevacizumab resulted in significant anatomical and functional improvements in eyes with centre-involving diabetic macular edema (CI-DME). Over three months, mean best-corrected visual acuity (BCVA) improved from 0.50 ± 0.095 to 0.67 ± 0.088 , central macular thickness (CMT) decreased from $401.9 \pm 87.6 \mu\text{m}$ to $329.5 \pm 23.2 \mu\text{m}$, and mean retinal sensitivity (RS), assessed by microperimetry, increased from $14.96 \pm 1.01 \text{ dB}$ to $16.50 \pm 1.39 \text{ dB}$ (all $p < 0.001$), suggesting that individuals with larger visual acuity gains also had superior retinal functional recovery. Overall, these findings reflect a consistent and statistically significant enhancement in both

visual acuity and retinal function, accompanied by a reduction in macular edema following bevacizumab therapy.

4.1 Structure–Function Correlation

Moderate yet statistically significant correlations were observed among the structural and functional parameters. Improvement in BCVA correlated positively with reduction in CMT (Spearman's $\rho = 0.340$, $p = 0.0137$), indicating that anatomical recovery was associated with matching functional visual improvements and with the gain in retinal sensitivity ($\rho = 0.412$, $p = 0.004$). Conversely, a negative correlation was found between CMT reduction and sensitivity gain ($\rho = -0.367$, $p = 0.009$), suggesting that greater resolution of edema was associated with higher recovery of retinal function (Table 4).

Table 4: Comparison of structure–function correlations between this study and published literature.

Study	Year	N (eyes)	Correlated parameters	Reported ρ / p	Key finding
Present study	2025	52	BCVA–CMT, BCVA–RS, CMT–RS	0.340 ($p = 0.0137$); 0.412 ($p = 0.004$); –0.367 ($p = 0.009$)	Moderate BCVA–CMT and BCVA–RS correlations; inverse CMT–RS relationship
Vujosevic et al.	2006	45	CMT–microperimetry	≈ 0.40	Thinner retina associated with greater sensitivity
Sugimoto et al.	2016	56	RS–BCVA	≈ 0.35 ($p < 0.01$)	Retinal sensitivity predicts visual outcomes after anti-VEGF therapy
Pereira et al.	2019	24	Bevacizumab \times microperimetry	RS increased 11.7 \rightarrow 16.3 dB ($p < 0.01$)	Functional recovery parallels anatomical improvement
Midena et al.	2024	58	OCT–microperimetry	0.38 ($p < 0.05$)	Microperimetry reflects macular structural recovery
Wang et al.	2022	—	Meta-analysis (CMT–VA)	0.30–0.50	Weak-to-moderate but consistent VA–CMT relationship
DRCR.net Protocol T	2015	660	CMT–BCVA	Not reported	Anti-VEGF therapy improves both BCVA and CMT significantly

Notes: BCVA = best-corrected visual acuity; CMT = central macular thickness; RS = retinal sensitivity; VA = visual acuity; VEGF = vascular endothelial growth factor; OCT = optical coherence tomography

Our findings align with prior reports demonstrating modest-to-moderate structure–function relationships in DME. Vujosevic et al. (2006) first established a topographic association between OCT-derived thickness and microparametric sensitivity.

Pereira et al. (2019) observed comparable functional recovery after monthly bevacizumab injections. Sugimoto et al. (2016) demonstrated that central retinal sensitivity serves as a predictor of visual outcomes post-anti-VEGF therapy, whereas Midena et al. (2024) validated that microperimetry detects nuanced functional improvements not evident in BCVA alone.

Wang et al. (2022) also stressed that even big meta-analyses only demonstrate weak to moderate links between CMT and visual acuity.

This means that other things, such as photoreceptor integrity, retinal ischemia, and brain injury, also affect how well someone recovers.

4.2 Comparison with Major Anti-VEGF Trials

Our results are consistent with the Diabetic Retinopathy Clinical Research Network (DRCR.net) Protocol T (2015), which showed significant improvements in BCVA and CMT with anti-VEGF medicines.

While microperimetry was not assessed in that experiment, our work expands these findings by recording enhancements over the wider macula, suggesting that functional recovery transcends foveal vision alone.

4.3 Clinical Implications

The present results strengthen real-world evidence supporting bevacizumab as an effective and accessible therapy for treatment-naïve CI-DME. Clinically, microperimetry complements traditional visual acuity testing by mapping localised retinal function and identifying subclinical improvement earlier in treatment.

Its demonstrated responsiveness after bevacizumab therapy supports its use as an adjunct outcome measure for assessing therapeutic efficacy and patient-reported quality of vision.

4.4 Limitations

The study's main limitations include a relatively small sample size, short follow-up of three months, and absence of a control arm. Microperimetry is inherently operator-dependent and subject to a learning effect, although testing protocols were standardised to minimise bias.

Larger, longer-term, and multicentre studies integrating multimodal imaging—such as OCT-angiography and photoreceptor integrity line analysis—are warranted to further clarify the temporal structure–function dynamics.

4.5 Strengths of the Study

Focusing on treatment-naïve eyes reduces confounding effects from previous therapies like laser therapy or corticosteroids.

The constant treatment regimen and objective OCT and microperimetry measurement improve internal validity.

The modest correlations show that structural repair alone does not entirely predict visual improvement, emphasising the need to include functional measurements like microperimetry to understand visual recovery.

4.6 Future Directions

For structural modifications to effect quality of life, future research should involve prolonged observation periods and patient-reported visual function markers. Functional indicators like microperimetry and comparative anti-VEGF medication and dosage studies may enhance diabetic macular edema treatment.

5. Conclusions

Three months of bevacizumab therapy resulted in significant improvements in visual acuity, macular thickness, and retinal sensitivity in treatment-naïve cases of CI-DME.

The moderate correlations observed among BCVA, CMT, and microperimetry outcomes suggest that anatomical and localised functional recovery happen simultaneously.

These findings are consistent with the existing literature, highlighting microperimetry as a crucial tool for the comprehensive assessment of anti-VEGF therapy in DME.

Ethical approval

Ethical approval was obtained from the Institute Ethics Committee.

Clinical Trials Registry-India (CTRI) Registration No.

CTRI/2023/10/058435

Conflict of interests

The authors declare that they have no financial or personal relationships that could be construed as a potential conflict of interest regarding the work presented in this manuscript. The research was conducted independently without any external funding or influence from commercial entities.

Acknowledgement

We would like to thank the staff of the Institute for their assistance in participant recruitment and data collection. Special thanks to the patients who participated in this study, making this research possible.

References

- Brown, D. M., Kaiser, P. K., Michels, M., Soubrane, G., Heier, J. S., Kim, R. Y., Sy, J. P., & Schneider, S. (2006). Ranibizumab versus verteporfin for neovascular age-related macular degeneration. *The New England Journal of Medicine*, 355(14), 1432–1444. <https://doi.org/10.1056/NEJMoa062655>
- Diabetic Retinopathy Clinical Research Network, Wells, J. A., Glassman, A. R., Ayala, A. R., Jampol, L. M., Aiello, L. P., Antoszyk, A. N., Arnold-Bush, B., Baker, C. W., Bressler, N. M., Browning, D. J., Elman, M. J., Ferris, F. L., Friedman, S. M., Melia, M., Pieramici, D. J., Sun, J. K., & Beck, R. W. (2015). Aflibercept, bevacizumab, or ranibizumab for diabetic macular edema. *The New England Journal of Medicine*, 372(13), 1193–1203. <https://doi.org/10.1056/NEJMoal1414264>
- Ferrara, N., & Adamis, A. P. (2016). Ten years of anti-vascular endothelial growth factor therapy. *Nature Reviews Drug Discovery*, 15(6), 385–403. <https://doi.org/10.1038/nrd.2015.17>
- Ihsan, G., Kwartika, A., Widyanatha, M. I., Virgana, R., Iskandar, E., & Kartasasmita, A. S. (2024). Early response of anti-vascular endothelial growth factor (anti-VEGF) in diabetic macular edema management: Microperimetry and optical coherence tomography findings—A pilot study at the National Eye Center of a third-world country. *BMC Ophthalmology*, 24(1), 551. <https://doi.org/10.1186/s12886-024-03744-8>
- Laishram, M., Srikanth, K., Rajalakshmi, A., Nagarajan, S., & Ezhumalai, G. (2017). Microperimetry – A new tool for assessing retinal sensitivity in macular diseases. *Journal of Clinical and Diagnostic Research (JCDR)*, 11(7), NC08–NC11. <https://doi.org/10.7860/JCDR/2017/25799.10213>
- Magliano, D. J., Boyko, E. J., & International Diabetes Federation 10th edition Scientific Committee. (2021). Global picture. In *IDF Diabetes Atlas* (10th ed.). International Diabetes Federation. <https://www.ncbi.nlm.nih.gov/books/NBK581940/>
- Midena, E., Frizziero, L., Torresin, T., & Pilotto, E. (2024). Microperimetry as a biomarker of macular function in diabetic macular edema: Correlation with OCT and treatment outcomes. *Frontiers in Ophthalmology*, 3, Article 1197448. <https://doi.org/10.3389/fopht.2024.1197448>
- Mitchell, P., Bandello, F., Schmidt-Erfurth, U., Lang, G. E., Massin, P., Schlingemann, R. O., Sutter, F., Simader, C., Burian, G., Gerstner, O., Weichselberger, A., & RESTORE Study Group. (2011). The RESTORE study: Ranibizumab monotherapy or combined with laser versus laser monotherapy for diabetic macular edema. *Ophthalmology*, 118(4), 615–625. <https://doi.org/10.1016/j.optha.2011.01.031>
- Nguyen, Q. D., Brown, D. M., Marcus, D. M., Boyer, D. S., Patel, S., Feiner, L., Gibson, A., Sy, J., Rundle, A. C., Hopkins, J. J., Rubio, R. G., Ehrlich, J. S., & RISE and RIDE Research Group. (2012). Ranibizumab for diabetic macular edema: Results from two phase III randomized trials—RISE and RIDE. *Ophthalmology*, 119(4), 789–801. <https://doi.org/10.1016/j.optha.2011.12.039>
- Pereira, F., Godoy, B. R., Maia, M., & Regatieri, C. V. (2019). Microperimetry and OCT angiography evaluation of patients with ischemic diabetic macular edema treated with monthly intravitreal bevacizumab: A pilot study. *International Journal of Retina and Vitreous*, 5, 24. <https://doi.org/10.1186/s40942-019-0176-9>
- Sugimoto, M., Tsujikawa, A., Miyamoto, K., Hata, Y., & Yoshimura, N. (2016). Importance of central retinal sensitivity for prediction of visual outcome after anti-VEGF therapy for diabetic macular edema. *PLOS ONE*, 11(7), e0159771. <https://doi.org/10.1371/journal.pone.0159771>
- Sun, H., Saeedi, P., Karuranga, S., Pinkepank, M., Ogurtsova, K., Duncan, B. B., Stein, C., Basit, A., Chan, J. C. N., Mbanya, J. C., Pavkov, M. E., Ramachandaran, A., Wild, S. H., James, S., Herman, W. H., Zhang, P., Bommer, C., Kuo, S., Boyko, E. J., & Magliano, D. J. (2022). *IDF Diabetes Atlas: Global, regional, and country-level diabetes prevalence estimates for 2021 and projections for 2045*. *Diabetes Research and Clinical Practice*, 183, 109119. <https://doi.org/10.1016/j.diabres.2021.109119>
- Udaondo, P., Parravano, M., Vujosevic, S., Zur, D., & Chakravarthy, U. (2022). Update on current and future management for diabetic maculopathy. *Ophthalmology and Therapy*, 11(2), 277–298. <https://doi.org/10.1007/s40123-022-00460-8>
- Vujosevic, S., Bottega, E., Casciano, M., Pilotto, E., Convento, E., & Midena, E. (2010). Microperimetry and fundus autofluorescence in diabetic macular edema: Subthreshold micropulse diode laser versus modified ETDRS laser photocoagulation. *Retina (Philadelphia, Pa.)*, 30(6), 908–916. <https://doi.org/10.1097/I AE.0b013e3181c96986>
- Vujosevic, S., Midena, E., Pilotto, E., Radin, P. P., Chiesa, L., & Cavarzeran, F. (2006). Diabetic macular edema: Correlation between microperimetry and optical coherence tomography findings. *Investigative Ophthalmology & Visual Science*, 47(7), 3044–3051. <https://doi.org/10.1167/iovs.05-1141>
- Wang, P., Xu, Y., Chen, Z., & Zhang, X. (2022). Relationship between macular thickness and

- visual function in diabetic macular edema: A meta-analysis. *Ophthalmology and Therapy*, 11(4), 1567–1582. <https://doi.org/10.1007/s40123-022-00525-8>
- Wells, J. A., Glassman, A. R., Ayala, A. R., Jampol, L. M., Bressler, N. M., Bressler, S. B., Brucker, A. J., Ferris, F. L., Hampton, G. R., Jhaveri, C., Melia, M., Beck, R. W., & Diabetic Retinopathy Clinical Research Network. (2016). Aflibercept, bevacizumab, or ranibizumab for diabetic macular edema: Two-year results from a comparative effectiveness randomised clinical trial. *Ophthalmology*, 123(6), 1351–1359. <https://doi.org/10.1016/j.ophtha.2016.02.022>
- Wong, T. Y., Cheung, C. M. G., Larsen, M., Sharma, S., & Simó, R. (2016). Diabetic retinopathy. *Nature Reviews Disease Primers*, 2, 16012. <https://doi.org/10.1038/nrdp.2016.12>
- Yau, J. W. Y., Rogers, S. L., Kawasaki, R., Lamoureux, E. L., Kowalski, J. W., Bek, T., Chen, S. J., Dekker, J. M., Fletcher, A., Grauslund, J., Haffner, S., Hamman, R. F., Ikram, M. K., Kayama, T., Klein, B. E. K., Klein, R., Krishnaiah, S., Mayurasakorn, K., O'Hare, J. P., & Wong, T. Y. (2012). Global prevalence and major risk factors of diabetic retinopathy. *Diabetes Care*, 35(3), 556–564. <https://doi.org/10.2337/dc11-1909>